



TrueKast Total Contact Casting System

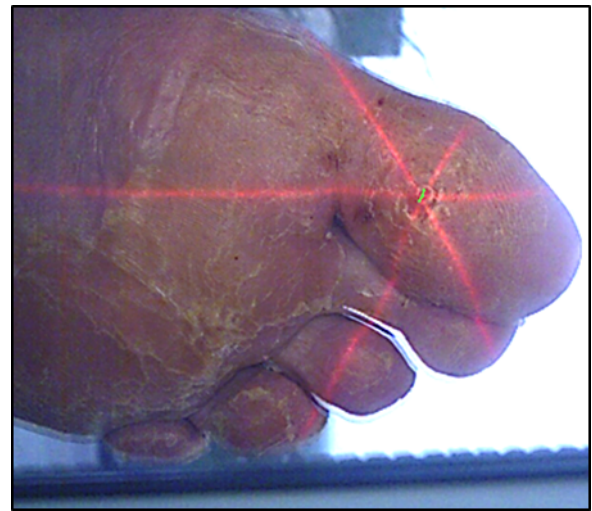
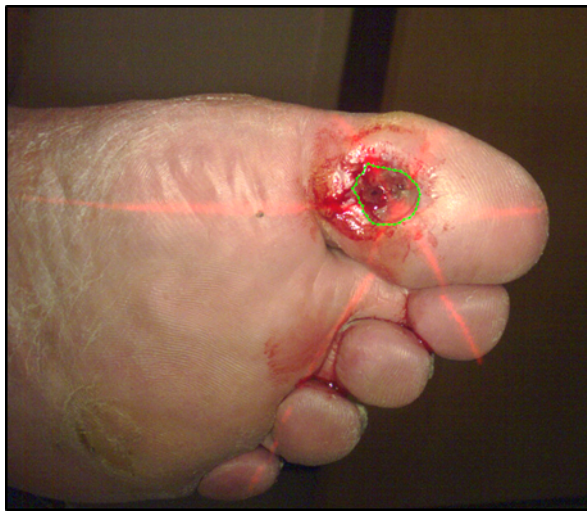www.truekast.com

Case Treatment Review

Cleveland Foot & Ankle Clinic / Kent State College of Podiatric Medicine - Cleveland Ohio

Clinician: Dr. Windy Cole, DPM

Adjunct Faculty & Wound Care Program Director Cleveland Foot & Ankle Clinic



The patient is a 55-year-old diabetic male with Wagner Grade 1 ulcer of the plantar aspect of the left great toe. Ulcer duration is over one year. Patient had 5 weeks of therapy including the TrueKast with Quicksaw Technology Total Contact Casting System until healing occurred.

Date of Treatment	Length (mm)	Width (mm)	Depth (mm)	% Volume Decrease
02/20/18	14	13	8	
03/16/18	8	6	6	80%
04/03/18	1	2	0	99%
04/10/18	Healed			

WoundKair Concepts, Inc.

Phone: 1-866-968-6352 | Fax: 1-866-968-6353

www.woundkair.com | Email: customerservice@woundkair.com