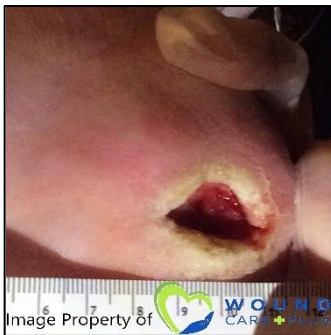
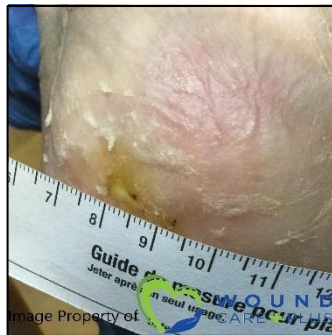
Wound Care Plus, LLC
Kansas, Missouri, Nebraska, Iowa, Arkansas, Oklahoma, Illinois Martha
R. Kelso, RN, HBOT, CEO, WCP

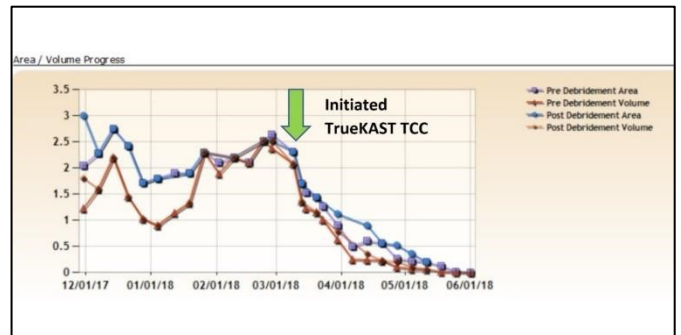
Wound Care Plus, LLC is a health care company operated by health care people. Our experience and commitment to excellence will help you provide better and more complete care. We believe proper, direct treatment is vital. On-going care and prevention is essential to good health and healing. That’s why we provide wound care education, training, documentation, and consultation utilizing advanced wound modalities for our wound care programs coupled with quality assurance reviews. Seth R. Snowden FNP is an advanced wound specialist for Wound Care Plus, LLC serving the greater Springfield, MO geographic region. Seth’s background includes an emphasis on Family and Occupational Medicine and a history of neurological, general surgical, trauma/emergency services and orthopedics.



Before Picture
November 30, 2017



After Picture
June 1, 2018



Wound Trajectory
TrueKast Total Contact Cast System
Initiated on March 13, 2018.

Case is ongoing treatment of a Diabetic wound of the right heel that has been present for 2 years. Wound Care Plus, LLC started treating the patient in November 2017. Calcium alginate was the treatment recommended on the first visit. Xray prior to application of total contact cast was negative for osteomyelitis and positive for a heel spur. ABI 0.9. Client propels self in wheelchair utilizing right heel for mobility. Patient is obese with poor nutritional intake. Physical therapy consulted for strength and mobility training. At time of application of cast, treatment was Santyl and calcium alginate covered with an ABD pad. Quality of tissue was deteriorating.

Utilizing the TrueKAST with Quicksaw Technology Total Contact Cast System along with standard of care principals (i.e. synergistic debridement, moist wound healing, appropriate dressing selection) the wound has had significant reduction in area and volume. This significant reduction has not occurred in the previous two years despite standard of care being utilized. The wound was resurfaced on June 1, 2018 and client was discharged off caseload.